



PATIENT

Arlo Metz

PRESENTING CLINICAL SIGNS

- Grade 2/6 murmur, coughing
- Medications: none

SPECIES

Canine

Abnormal PE/Chem/CBC/UA Results: not available

BREED

Beagle Mix

SEX

MN

AGE

9yr

WEIGHT

43lb

ULTRASONOGRAPHIC EXAMINATION OF THE HEART

| CANINE CARDIAC PARAMETERS | MR VMAX (m/s) | TR VMAX (m/s) | LA/AO M-mode | LA/AO (Heart Base; Swe) | FS (%) | EF (%) | EPSS (cm) |
|---------------------------|---------------|---------------|--------------|-------------------------|----------------------|--|--|
| NORMAL PARAMETER | 4.5-5.5 | <2.7 | 1.3 | Up to 1.6 | 28-40 | 40-100 | <0.6 |
| PATIENT | -- | <2.0 | -- | 1.3 | 43 | 75 | 0.2 |
| CANINE CARDIAC PARAMETERS | HR (BPM) | AV VMAX (m/s) | PV MAX (m/s) | BODY WEIGHT | LAD LA MAX 4 Chamber | LVIDd Avg; 2D and m-mode short axis (cm) | LVIDs Avg; 2D and m-mode short axis (cm) |
| NORMAL PARAMETER | 50-100 | 0.7-1.7 | 0.7-1.6 | | | | |
| PATIENT | 132 | 1.8 | 1.7 | 43lb | 3.8 | 3.5 | -- |

INTERPRETED BY

R. McKenzie Daniel,
DVM, DABVP
(Canine and Feline)

Cardiac Presentation

The echocardiogram in this patient demonstrated normal left atrial size based on 2 different LA measurement methods. Chamber volumes and echogenicity were normal. The cranial and caudal mitral valve leaflets presented mild thickening consistent with endocardiosis. Doppler indicated eccentric insufficiency. The left ventricle presented thicknesses with linear contour and was not dilated nor restricted. The myocardium presented normal echogenicity without subjective evidence of significant fibrotic or ischemic disease. Contractility of the ventricular walls was adequate and in normal range for this patient evidenced by the fractional shortening measurement and subjective evaluation of the different regions of the myocardium. The left ventricular outflow tract demonstrated normal laminar flow and subjective structural integrity. The right atrium and auricle revealed normal size, structure and content. No evidence of masses was noted or chamber overload. Tricuspid valvular assessment demonstrated adequate linear morphology. Minor TR on Doppler. The right ventricle was of normal size (1/3 diameter of LV), chordae structure, myocardial echogenicity and thickness. Pulmonic tract assessment revealed normal valve structure, laminar flow, and diameter (approx.1:1 pa/ao ratio). No visible pericardial or free pleura fluid was noted. No echographically detectable evidence of infiltrative disease was visible. The cranial mediastinum and pericardial regions were free of masses in the visible window.

IMAGING PERFORMED BY

Dr Ken Leal

HOSPITAL NAME

VCA Blirstown

REFERRING VET

Dr Clegg

INVOICE
24120

DATE
03/05/2026



PATIENT ULTRASONOGRAPHIC FINDINGS

Arlo Metz **Primary**

- Chronic mitral valve disease (B1)
- Minor TV insufficiency - no evidence of pulmonary hypertension

SPECIES

Canine

INTERPRETATION OF THE FINDINGS & FURTHER RECOMMENDATIONS

BREED

Beagle Mix

The cause of the murmur is subjective mild chronic degenerative valvular changes with secondary MR. No evidence of additional issues such as DCM criteria, LV systolic dysfunction or clinical pulmonary hypertension. The lack of left atrial enlargement implies that the risk of complication secondary to mitral valve insufficiency is relatively low at this time and, without current clinical signs, indicates that medical therapy is not required at this stage. Prognosis at this stage is variable and serial sonographic monitoring is recommended with a recheck echocardiogram in 6 months, sooner if clinical signs suggestive of heart disease develop.

SEX

MN

AGE

9yr

No anesthetic contraindications. Suggested anesthetic protocol may include opioid or Benzodiazepine pre-med, induction with Propofol or Alfaxalone, and appropriate gas anesthesia with avoidance of alpha 2 agonists.

WEIGHT

43lb

INTERPRETED BY

R. McKenzie Daniel, DVM, DABVP (Canine and Feline)

IMAGING PERFORMED BY

Dr Ken Leal

HOSPITAL NAME

VCA Blirstown

REFERRING VET

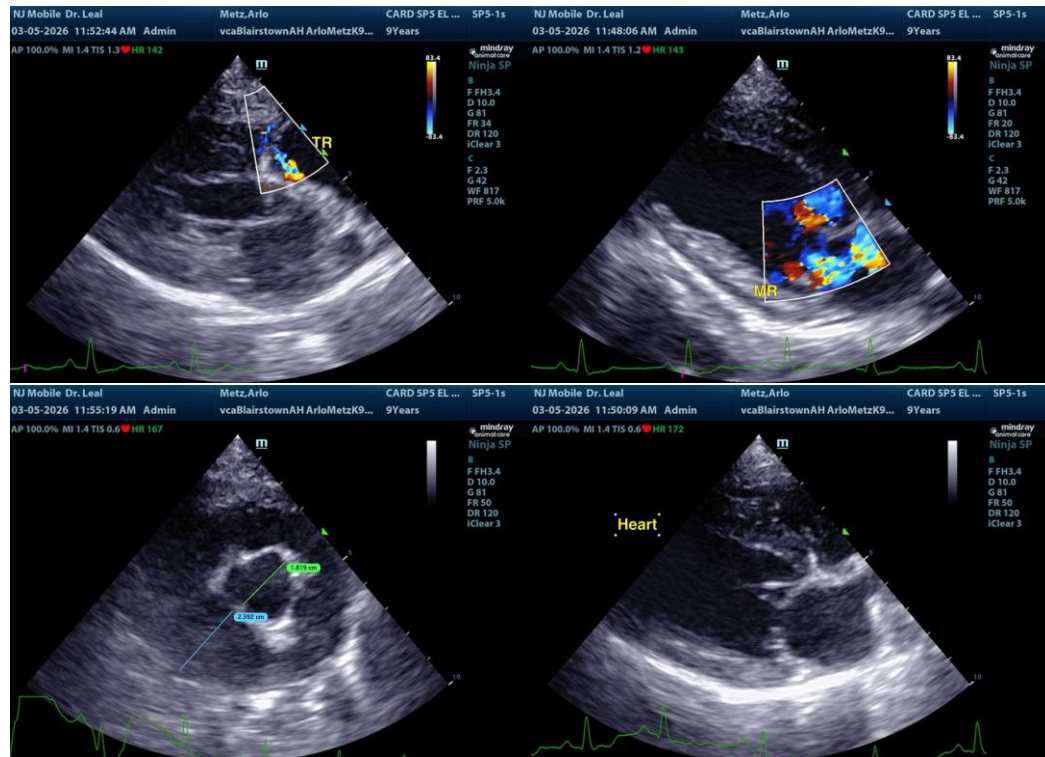
Dr Clegg

INVOICE

24120

DATE

03/05/2026



The information and recommendations provided are based on the images presented by the referring veterinarian/sonographer. No evaluation can be communicated regarding pathology that was not



PATIENT

Arlo Metz

visible in the image/video clips provided.

Thank you for this referral. If the clinical or image interpretation does not parallel your findings or if I can be of any further assistance, please contact me.

SPECIES

Canine

R. McKenzie Daniel, DVM, DABVP (Canine/Feline Practice)
info@sonopath.com

BREED

Beagle Mix

SEX

MN

AGE

9yr

WEIGHT

43lb

INTERPRETED BY

R. McKenzie Daniel,
DVM, DABVP
(Canine and Feline)

**IMAGING
PERFORMED BY**

Dr Ken Leal

HOSPITAL NAME

VCA Blirstown

REFERRING VET

Dr Clegg

INVOICE

24120

DATE

03/05/2026